OSTEOSARCOMA: A FLUID CYTOLOGY CASE REPORT

Dr T.Mitila 1st year PG; Dr Vimal Chander MD, Dr Chitra Srinivasan MD
Department of Pathology, Saveetha Medical College

INTRODUCTION: Osteosarcoma is the most common aggressive primary malignant bone tumor showing bimodal pattern of age distribution, characterized by the formation of disorganized immature bone or osteoid tissue from mesenchymal tumour cells. It usually occurs in the appendicular skeleton involving the metaphysis of long bones, most commonly the distal femur and proximal tibia of adolescent patients.

Case Report

A 20-year-old male presented to the Orthopaedic OPD with complaints of swelling over the right knee for 6 months. The patient had a history of trauma 1 month back, since when he developed pain. Examination revealed a tender 15x10x8 cm swelling palpable on the distal femur. A core needle biopsy from the lesion was performed, and fluid obtained from the biopsy site was sent for cytological examination. Cell block preparation was also done.

Investigations

- Biochemical: ALP- 130 IU/L.
- Radiological: MRI- Ill-defined heterogenous lesion arising from the posterior aspect of distal femur meta-epiphyseal region, extending into soft tissue.
  PET-CT- Features consistent with right femoral osteosarcoma

Gross

- Fluid cytology- Received 15 ml of reddish coloured fluid.
- Core needle biopsy- Received multiple grey white soft tissue fragments, on aggregate measuring 3x3x2 cm.

Microscopy

- Fluid cytology-. Highly cellular smears. Few tumour cells were seen surrounding occasional osteoid-like material. Few tumour giant cells with markedly pleomorphic nuclei were seen. Scattered osteoclastic giant cells were also seen in a background of abundant hemorrhage.

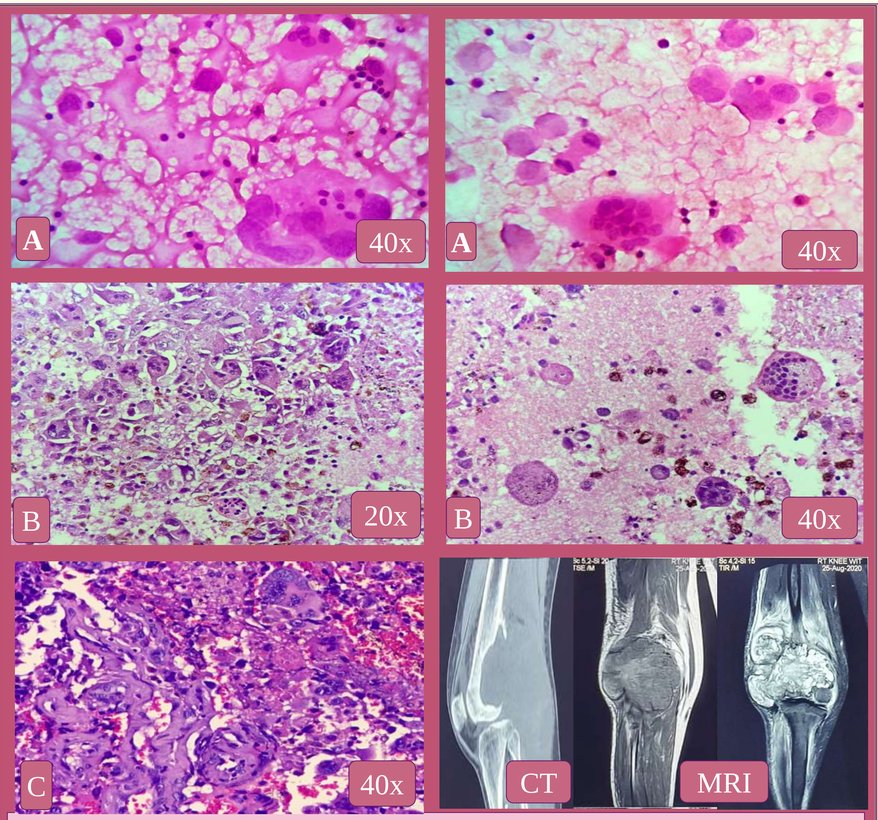

IMPRESSION:

- A- Fluid aspirated from swelling – Smears positivity for malignancy- Features suggestive of Osteosarcoma
- B- Cell block- Features of osteosarcoma- showing giant cell predominance
- C- Core needle biopsy- Right distal femur – Features of osteosarcoma, probably giant cell rich.

Discussion

Cytological evaluation of fluids can be used for distinction of benign, reactive conditions from malignancies. Cell block is a simple, cost effective preparation and can be used as adjuncts to smear for establishing a more definitive cytopathological diagnosis, providing the best milieu for morphological interpretation, with less background staining. Common variants of osteosarcoma include osteoblastic, chondroblastic and fibroblastic types depending on the cellular atypia and the type of the extracellular matrix, produced by the tumour cells. Giant cell-rich osteosarcoma (GCRO), a rare histologic variant, accounting for only 1%–3% of conventional osteosarcoma, is an undifferentiated high-grade sarcoma with numerous osteoclast-like giant cells and variable amount of tumour osteoid.

Conclusion

Although the diagnosis of osteosarcoma is confirmed by the histopathological findings of biopsy, this case presents a rare scenario of fluid from the swelling revealing the tumour diagnosis. Cytologic examination may help reach the correct diagnosis if the smears and cellblock sections are carefully evaluated for certain helpful cytomorphologic features, particularly osteoid matrix.

Reference

1. Mallick A, Shah N, Mahmud SA, Das SK. Giant cell-rich osteosarcoma–A rare case. Journal of Oral and Maxillofacial Pathology: JOMFP. 2020 Feb;24(Suppl 1):S67
2. Domanski HA, Åkerman M. Fine-needle aspiration of primary osteosarcoma: A cytological-histological study. Diagnostic Cytopathology. 2005 May;32(5):269-75.
3. Santwani PM, Vachhani JH. Analysis of diagnostic value of cytological smear method versus cell blocks method in body fluid cytology: study of 150 cases. Ethiopian journal of health sciences. 2014 Apr 14;24(2):125-30.