MUCINOUS BREAST CARCINOMA : DIAGNOSED ON FNAC

Dr. Priya Singh Lohchab[1] , Dr Vaanika[2], Dr. Tanu Agrawal [3]
1-Junior Resident, 2-Associate Professor, 3-Professor and Head of Department
Department of Pathology, SRMS IMS , Bareilly

INTRODUCTION

Mucinous carcinoma of the breast is uncommon variant of breast carcinoma accounting for 2% of all breast carcinomas. It have been described in pure form and as mixed mucinous-ductal type . MC usually occurs in elderly female median age being older than 55- 60 years. This tumor shows characteristic features of mucin production by the tumor and in general mucinous component is 50% or more.

CASE REPORT

We hereby present a case of 57 year old female presented with the chief complains of gradually progressive, painful, left breast lump from 1 year. On examination a large breast lump of approximately 6x6 cm in size, firm to hard in consistency was felt in the upper quadrant of left breast. The overlying skin was normal and nipple was not retracted. No axillary lymph nodes were palpable . The clinical diagnosis of carcinoma in left breast was made. FNAC of mass was adviced. Cytomorphological features favored mucionous carcinoma breast which was confirmed on histology.

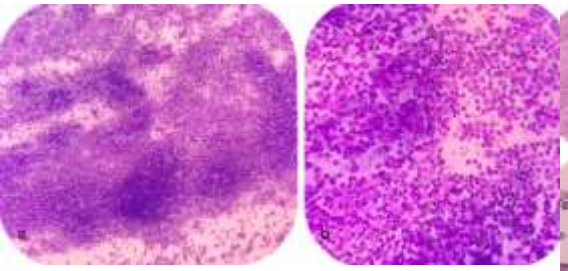

(A)High Power, Moderately cellular with clusters of tumor cells against a rich mucinous background and (B)Low Power

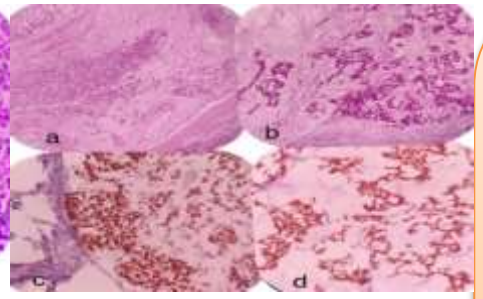

(a) (b)Micrograph of a case of mucinous carcinoma showing small clusters and individual cells floating in large amount of mucin on H& E stain (c) (d) Mucinous Carcinoma expressed on Estrogen Receptor

DISCUSSION

On cytological evaluation, it is important to differentiate mucinous carcinoma from other mucin containing benign and malignant lesions of breast. Mucinous carcinomas usually show higher cellularity, more single tumour cells, three-dimensional clusters of tumour cells, and mild to marked nuclear atypia. In mixed mucinous carcinoma, the amount of mucin is usually scanty. The nuclear atypia is more conspicuous with prominent nucleoli and there may be presence of necrosis.It is observed that in mucinous carcinoma, cell clusters comprised uniform cells with rounded contours.The presence of Chicken wire or thin walled vessels has been found in pure and mixed mucinous carcinoma.

CONCLUSION

In conclusion, presence of mucin in breast cytology warrants the possibility of mucinous carcinoma. Appropriate interpretation of cytological findings is important to differentiate from benign as well as malignant mimickers and to arrive at the correct diagnosis.

REFERENCE

1. Diab SG, Clark GM, Osborne CK, Libby A, Allred DC, Elledge RM. Tumor characteristics and clinical outcome of tubular and mucinous breast carcinomas. J Clin Oncol 1997;17:1442-8.
2. Tellem M, Nedwich A, Amenta PS, Imbriglia JE. Mucin-producing carcinoma of the breast. Tissue culture, histochemical ands electron microscopic study. Cancer 1966;19:573-84