COMPARATIVE STUDY OF CELL BLOCK VERSUS CONVENTIONAL SMEAR IN CYTODIAGNOSIS OF SEROUS EFFUSIONS

Dr. Shaziya Huma[1], Dr Hema Pant[2] (1-Junior Resident, 2-Professor)
Department of Pathology, Shri Ram Murti Smarak Institute of Medical, U.P. Sciences, Bareilly

BACKGROUND

Cell block preparation increases the sensitivity of detecting malignancies and also has the ability to reduce false-positive interpretations. The advantages of the cell block technique are preservation of tissue architecture and obtaining multiple sections for special stains and immunohistochemistry.[1, 2]
Cell block method is simple cost effective which requires no extra material compared to other methods[1,2] Cell block gives excellent cellular and nuclear morphology and chromatin details.[3,4]

AIM

The study aims to compare conventional smear technique from cell block technique.

MATERIAL AND METHOD

This was a prospective study including 104 cases after meeting inclusion criteria.

Conventional smear technique-
Slides were stained with May-Grunwald-Giemsa stain and papanicolaou stain.

Cell block technique-
Sections were prepared from this cell button and were stained with hematoxylin and eosin stain.

RESULT

Age ranges between 5 to 92 years with maximum number of cases between 51 to 60 years. Females were predominantly affected with 63 cases and males with 41 cases.

The present study demonstrates 25(24.03%) cases of transudates, 43(41.34%) cases of exudates and 36(34.61%) cases in which protein level was not performed.

Conventional smear showed 16 cases positive for malignancy among 104 cases, whereas cell block showed 23 positive cases.

In the study sensitivity, specificity, PPV and NPV for conventional smear was 48.48%, 100%, 100% and 80.68% respectively and for cell block was 69.70%, 100%, 100% and 87.65%.

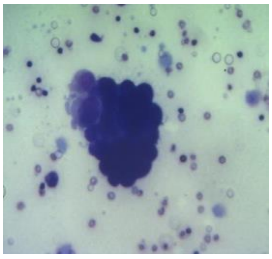

Figure showing 3-D cluster of malignant cells in conventional smears (adenocarcinoma) (Giemsa 40x)

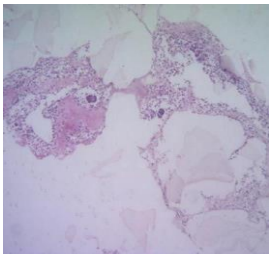

Figure showing malignant cells admixed with inflammatory cells in Cell Block- Adenocarcinoma (H&E 10x)

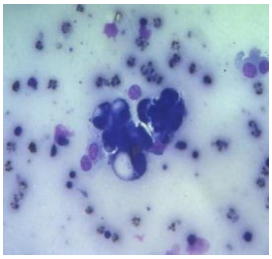

Figure showing signet ring cells of adenocarcinoma in conventional smears. (Giemsa 40x)

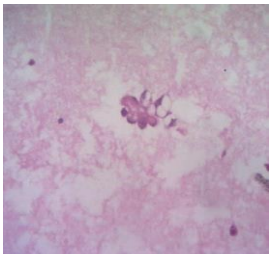

Figure XVII showing signet ring cells in cell block (H&E 40x)

DISCUSSION & CONCLUSION

On comparing the accuracy, cell block technique and smear examination gave different results for malignancy positivity (90% vs 83% respectively).
For cytological examination of all serous effusions, smears should be supplemented with cell block to increase pickup rate especially if there is suspicion of malignancy.
It is concluded from this study that cell block along with routine cytology increases sensitivity which can be further increased if IHC is applied.

REFERENCES

1. Kushwaha R, Shashikala P, Hiremath S, Basavaraj HG. The cells in the pleural fluid and their value in the differential diagnosis. J Cytol 2008;25:138-43.
2. Shivakumarswamy U, Arakeri SU, Mahesh H Karigowdar MH, Yelikar BR. Diagnostic utility of the cell block method versus the conventional smear study in pleural fluid cytology. J Cytol 2012;29:11-15.
3. Sallach SM, Sallach JA, Vasquez E, Schultz L, Kvale P. Volume of pleural fluid required for diagnosis of pleural malignancy. Chest 2002;122:1913-7.
4. Koss LG. Effusions in the absence of cancer. In: Diagnostic Cytology and its Histopathologic Bases, 5th edition. Edited by Koss LG, Melamed MR, Vol 2, Philadelphia: J. B. Lippincott, 2006.919-948.